

The role of magnetic resonance in the staging of Klatskin tumors

Staging of klatskin tumor with MR

Levent Soydan¹, Mehmet Torun², Kamil Canpolat¹, Turgay Oner¹, Umut Kına², Ismail Ege Subasi³¹Department of Radiology, Haydarpasa Numune Training and Research Hospital²Department of General Surgery, Haydarpasa Numune Training and Research Hospital³Department of Gastroenterology, Istanbul Kartal Kosuyolu High Speciality Educational and Research Hospital
Istanbul, Turkey

Abstract

Aim: In this study, it was aimed to investigate the diagnostic accuracy of preoperative staging of Klatskin tumors (KT) with Magnetic Resonance (MR) and MR cholangiopancreatography (MRCP) with reference to surgical and histopathological results.

Material and Methods: This study was conducted by retrospectively reviewing preoperative dynamic contrast-enhanced (DCE) MR and MRCP examinations of 25 patients who were operated with the pre-diagnosis of KT and diagnosed as KT by postoperative histopathology at the Haydarpasha Numune Training and Research Hospital between January 1, 2012 and December 31, 2019. Two radiologists evaluated the longitudinal extension of the tumor along the common bile duct and the intrahepatic biliary tract involvement. Consensus was achieved on Bismuth-Corlette (BC) typing and TN staging. The diagnostic performances of the MR/MRCP findings were assessed with reference to surgical exploration and resected specimens.

Results: Among 25 cases evaluated in the study, 12 (48%) were female, 13 (52%) were male, with a mean age of 61.96 ± 8.91 (minimum: 42, maximum: 81) years. The sensitivity of the MRCP in distinguishing between BC Type 3 and T1-Type 2 was 77.78%, the specificity was 78.57%, and the diagnostic accuracy was 78.26%. The sensitivity of dynamic MRI for T staging was 62.5%, specificity was 86.67% and diagnostic accuracy was 69.26%; In N staging, its sensitivity was 28.57%, specificity was 87.5% and accuracy was 60.57%.

Discussion: MRCP and DCE MR examination can be used for clinical staging of KTs to evaluate biliary extension and operability. In N staging, which is important for prognosis, its accuracy is limited.

Keywords

Diagnostic accuracy; Klatskin tumor; Magnetic resonance; Staging

DOI: 10.4328/ACAM.20542 Received: 2021-02-15 Accepted: 2021-04-01 Published Online: 2021-06-21 Printed: 2021-09-01 Ann Clin Anal Med 2021;12(9):963-968

Corresponding Author: Levent Soydan, Haydarpasa Numune Training and Research Hospital, Selimiye, Tibbiye street, No:23, 34668 Uskudar/Istanbul, Turkey.

E-mail: levent.soydan@gmail.com P: +90 5333956490

Corresponding Author ORCID ID: <https://orcid.org/0000-0002-8958-5118>

Introduction

Klatskin Tumor (KT) is the most common type of cholangiocarcinoma originating from the biliary epithelium at the hepatic duct confluence. The incidence is around 0.3-6 / 100000 with regional variations [1]. Various classifications based on the extension along bile ducts and vascular invasion have been proposed for KT to plan an optimal treatment approach and to predict the prognosis [2].

Currently, the only treatment in KT is R0 surgical resection for resectable tumors to prolong survival [2]. Preoperative imaging identifies non-resectable cases for palliative treatment and enables preoperative assessment of bile duct involvement in resectable cases. An accurate preoperative evaluation of tumor extension, parenchymal involvement and resectability is important for treatment planning. Multislice Computed Tomography (CT), Magnetic Resonance (MR) and endoscopic retrograde cholangiopancreatography (ERCP) are the most commonly used imaging techniques in preoperative staging of KTs [2,3]. MR-Cholangiopancreatography (MRCP) can be used to non-invasively evaluate the presence, degree and level of bile duct obstruction by displaying the biliary tree owing to the heavy T2W-related high contrast between bile ducts and the periphery [3,4]. Dynamic contrast-enhanced (DCE) MR is an alternative to CT in the detection of tumor, parenchymal and distant spread, and evaluation of vascular invasion.

The modified Bismuth-Corlette (BC) classification evaluates tumoral biliary infiltration and is the most widely used classification for KT, while the AJCC-TNM staging classifies patients according to prognosis and allows tailoring an appropriate treatment [5,6]. In addition, Memorial Sloan-Kettering Cancer Centre and Blumgart classifications can be used in the preoperative evaluation of KT by providing information about tumor resectability [6,7]. In this study, we aimed to evaluate the diagnostic performance of KT with MRCP and contrast-enhanced MRI according to TNM staging and BC classification, with reference to surgical and histopathological findings.

Material and Methods

This retrospective study was conducted with 25 patients who were operated with the pre-diagnosis of KT in Haydarpasha Numune Training and Research Hospital between January 1, 2012 and December 31, 2019 and were diagnosed with KT on postsurgical pathology. Ethical approval for this study was obtained from the Ethic Committee of our Institution.

Selection of patients

Twenty-five patients who were diagnosed as KT by postoperative histopathology and underwent MRCP and DCE MRI within 20 days before the operation were included in the study. Cases that did not meet these criteria were excluded from the study.

MRCP and Contrast-enhanced MRI Technique

All MR scans were performed with a 1.5T GE 760w Optima 4-channel phased-array abdominal coil (GE Healthcare, Milwaukee, USA). In MRCP examination, images were obtained using +/- 30° and 60° T2 weighted (T2W) thick slab turbo spin echo (TSE), breath hold thin slab coronal and axial T2W SSFE (single-shot fast spin echo) sequences in the coronal, oblique coronal and sagittal planes with breath hold. Breath-hold thin-

section T2W SSFE MRCP images covered a scan volume of approximately 60 mm³ at a time in 5 minutes. 3D MRCP images were obtained using the ASSET (array of spatial sensitivity technique) technique, respiratory triggering and navigator. These data were transferred to a workstation and 3D images rotating with 10° increments around the z-axis were created with the maximum intensity projection technique.

For DCE images 0.1 mmol/kg gadoteric acid (Dotarem, Guerbet, France) was given intravenously at a rate of 2 ml/sec and fat-suppressed 3D T1W Gradient Echo (GRE) images (LAVA, GE) at a slice-thickness of 5mm were acquired at 20-35 seconds, 45-60 seconds and 3 minutes for arterial, venous and equilibrium phases images, respectively. The imaging protocol is summarized in Table 1.

Image Analysis

All images were reviewed by two radiologists on the PACS workstation (GE Workstation). Two radiologists with 15 and 5 years of experience in abdominal MR imaging evaluated dynamic MR and MRCP images. Both radiologists knew that the patients had been operated, but were blinded to the postoperative results. The MR assessment of each case was reached by consensus of both radiologists.

KT was diagnosed as slightly hyperintense on T2A and hypointense on DCE T1A images. Continuous or segmental enhancement was noted along the involved biliary walls, especially in the arterial phase. In addition, loss of biliary ductal continuity, ductal obstruction, sudden and irregular narrowing of the distal common bile duct, prestenotic dilatation and irregular intraluminal filling defects were accepted as biliary involvement.

Both radiologists evaluated tumor extension along the common bile duct and intrahepatic bile ducts using the BC classification. Dilated bile ducts were correlated with axial/coronal T2W and axial DCE images. The KTs were classified as follows:

- Type I is contained in the common bile duct and does not extend to the biliary confluence (Figures 2),
- Type II involves proximal cystic duct and biliary confluence (Figure 1),
- Type IIIa extends proximally from the junction of cystic duct-common bile duct to the biliary confluence and the right hepatic duct and/or to the right secondary bile ducts,
- Type IIIb extends proximally from the junction of cystic duct-common bile duct to the biliary confluence and the left hepatic duct and/or to the left secondary bile ducts,
- Type IV extends proximal from cystic duct-common bile duct junction to biliary confluence and both hepatic ducts or showing multifocal bile duct involvement.

Axial and coronal DCE images were used for T and N staging and correlated with T2A sections when needed. Accordingly, T1 was defined for a tumor confined in the biliary canal, T2 for invasion of the biliary canal and adjacent hepatic parenchyma, T3 for invasion of the portal vein branch or hepatic artery, and T4 for the involvement of the main portal vein, common hepatic artery or secondary biliary ducts. The diagnosis of venous or arterial invasion was made when KT encased vascular structures > 180° (Figures 3).

In nodal staging, N1 was defined involvement of 1-3 regional lymph nodes (nodes near the common bile duct, cystic duct,

proper hepatic artery and portal vein), and N2 was defined as > 4 distant nodes. Metastatic involvement was defined in nodes with a short axis > 10 mm, with central necrosis or with hyperenhancement compared to liver parenchyma in the portal phase.

Reference Standard

The definitive diagnosis was made in all patients by histopathological examination. The TNM staging was done according to the 8. AJCC criteria. Klatskin typing was done according to the modified BC classification. Hepatobiliary surgical procedures were performed by two surgeons with 17 and 5 years of experience in this field. During the surgery, the biliary confluence was exposed, the vascular involvement was evaluated, and resection was performed in all cases. An intraoperative frozen histological examination of the resection margin was performed to ensure the R0 resection.

Statistical Analysis

Preoperative biliary and nodal involvement were compared with postoperative histopathological findings. Diagnostic performance sensitivity, specificity and diagnostic accuracy were calculated in all patients with radiological TNM staging and Klatskin typing. For statistical analysis, the NCSS (Number Cruncher Statistical System) 2007 (Kaysville, Utah, USA) program was used. Descriptive statistical methods (mean, standard deviation, median, frequency, percentage, minimum, maximum) were used while evaluating the study data. The McNemar test and diagnostic screening tests were used to compare qualitative data. Statistical significance was accepted as p <0.05.

Results

Among 25 patients, 12 (48%) were female, 13 (52%) were male, with a mean age of 61.96 ± 8.91 (range 42-81) years. The mean time between surgery and MRCP/MRI was 7 days. Patient characteristics are given in Table 2. All cases were adenocarcinoma. According to histopathology, 1 patient had type I, 14 patients had type II, 5 patients had type IIIa, and 5 patients had Type IIIb BC KT. The median survival was 841 (21 - 2555) days.

Evaluation of radiological and pathological TNM staging

On DCE/MR enhancement of segments with biliary involvement was observed in the arterial phase in 90% and in the portal phase in 95% of cases.

According to the histopathological T staging, 12% (n = 3) of cases were pT1, 56% (n = 14) were pT2, 28% (n = 7) were pT3 and 4% (n = 1) was pT4. According to MR staging 68% (n = 17) of cases were T2 and 32% (n = 8) was T3. No statistically significant difference was found between histopathology and MR findings (p > 0.05). While there were 34.8% cases

pathologically > = T3, there were 30.4% cases with > = T3 on MR. Three of 8 pT3 cases were understaged as T2 by MR (34.8% vs 21.7%).

Nine cases (36%) showed lymph node metastasis on pathology. According to the pathology results, 7 cases (28%) were diagnosed as N1, while radiology evaluated 2 cases (8%) as N1.

Extension of the Tumor along Biliary Tract

MRCP images were of sufficient diagnostic quality in all patients. On pathological examination Klatskin classification was as follows; 4% (n = 1) was type 1, 56% (n = 14) were type 2, 20% (n = 5) were type 3a and 20% (n = 5) were type 3b. The MR classification was as follows; 4.3% (n = 1) was type 1, 52.2% (n = 12) were type 2, 17.4% (n = 4) were type 3a and 26.1% (n = 6) were type 3b. No significant difference was found between MR findings and pathology results, (p > 0.05). Nine cases (39.1%) were pathologically classified as Type 3a-3b and 7 cases (30.4%) as Type 3a-3b on MR. The diagnostic performance of MRCP /MRI in evaluating BC typing and TN stages of KT is shown in Table 3.

Table 1. Imaging parameters for dynamic MR and MRCP

Parameter	No contrast T1A GRE	Dynamic images	Thick section (slab) axial T2A FSE	Thin section T2A axial + coronal SSFSE	3D MRCP (ASSET)
TR / TE	6/3.1	6/3.1	5000/103	536/98.8	2002/775
Section thickness	4.8	4.8	5.5	5.5	3.2
Flip Angle	12	12	160	90	90
FOV (cm)	43x34.4	43x34.4	43x43	38x38	36x36
Matrix	288x224	288x224	256x256	512x1920	288x192
NEX	0.72	0.72	1.00	0.62	0.50

Table 2. Descriptive characteristics of the patients in the study group

Age (Year)	61,96 ± 8,91
Gender	
Female	12 (%48,0)
Male	13 (%52,0)
Mortality	
No	7 (%28,0)
Yes	18 (%72,0)
Neutrophil (µL)	5304,80 ± 3030,01
Lymphocyte (µL)	1971,60 ± 718,94
Platelet (x10 ³ /mm ³)	272,32 ± 66,339
CRP (mg/L)	1,39 ± 1,34
Albumin (g/dL)	3,54 ± 0,70
Ca 19-9 (U / mL)	4959,87 ± 23968,11
CEA (ng/mL)	5,38 ± 8,98

Continuous numerical variables are shown with mean ± standard deviation values, and categorical variables with frequency (percentage) val-ues. Ca: Cancer Antigen, CEA: Carcinoembryonic antigen, CRP: C-reactive protein

Table 3. Radiological Performance According to TN Stages and Klatskin Type

	Sensitivity	Specificity	Positive predictive value	Negative predictive value	Accuracy	Kappa compliance
T stage	62,50	86,67	71,43	81,25	78,26	0,506
N stage	28,57	87,50	50,00	73,68	69,57	0,183
Klatskin Type	77,78	78,57	70,00	84,62	78,26	0,647

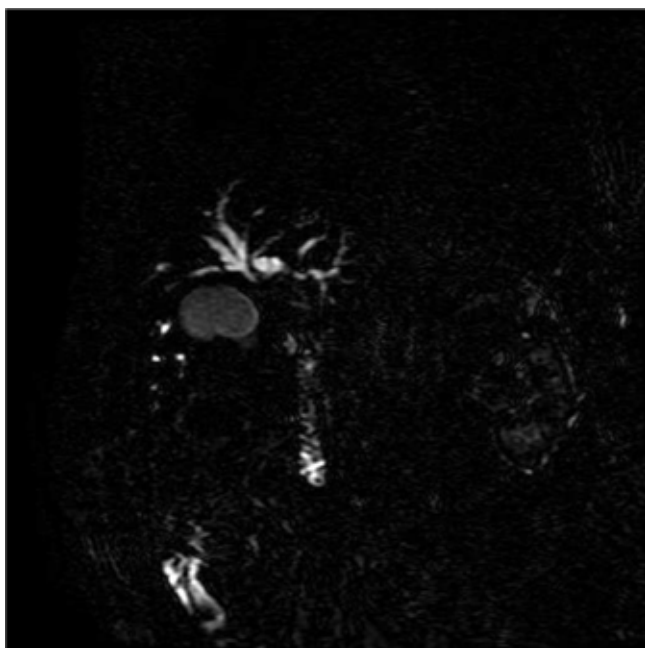


Figure 1. Coronal MRCP showing a BC Type II KT located at hilar biliary confluence with associated dilatation in both lobar intrahepatic ducts

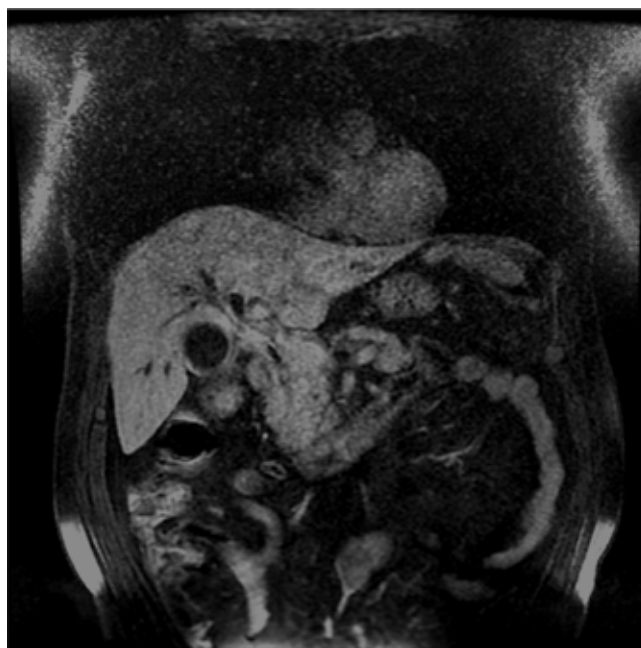


Figure 3. Contrast-enhanced and fat-suppressed coronal T1W image showing a T4 tumor with enhancement along the biliary wall and invasion of adjacent hepatic parenchyma

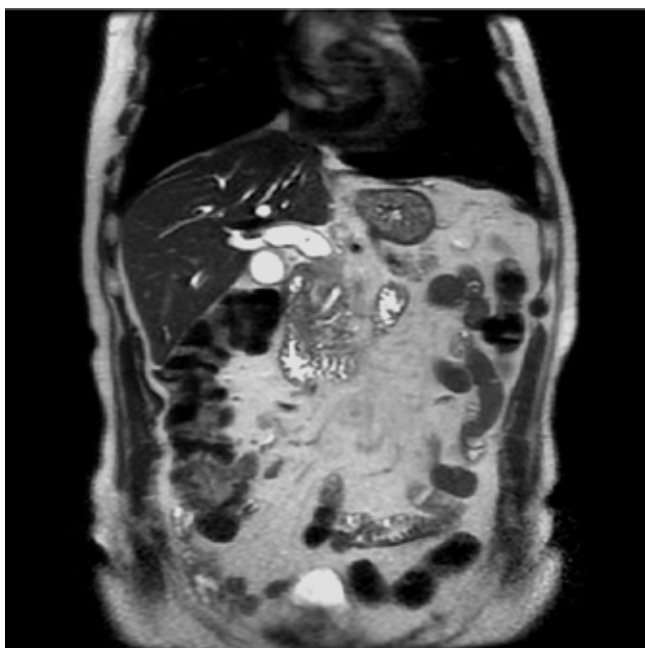


Figure 2. T2W coronal image showing a BC Type I KT located between cystic duct and hilar confluence causing dilatation in proximal common bile duct

Discussion

In this study, we found that the diagnostic accuracy of preoperative MR/MRCP in distinguishing BC Type 3 patients from Type 1 and Type 2 patients is 78.2%. In addition, the accuracy of the dynamic MR in distinguishing Klatskin T3 from T1 and T2 was 69.2% and the accuracy in differentiating between N1 and N0 was 60.6%. In previous studies, the accuracy of MRCP in detecting biliary tumor extension was reported as 71% -96% and its sensitivity was 92% [8-15]. Our results were consistent with those reported in previously published studies. Zidi et al. and Vogl et al reported that MRCP had an accuracy

of 70% and 95% for all BC types, respectively, with ERCP taken as a reference, and that MRCP tended to underdiagnose BC types [9, 10]. Lopera et al. and Lee et al., found that MRCP predicts bile duct involvement with an accuracy of 96% and 87.9%, respectively, using PTK as a reference [14,16]. Similar to our study, Park et al. took surgical and pathological results as a reference and reported that the diagnostic accuracy of combined use of DCE MR and MRCP was 87-90.7% [11]. Similar to other studies, our study also showed that MR tended to understage the BC type. One of the probable explanations for this may be the microscopic tumor infiltration that cannot be discerned on MR due to its low spatial resolution.

Concerning metastatic lymph node involvement, imaging methods have been reported to have low diagnostic accuracy. Noji et al., reported that in lymph nodes with short axis > 16 mm the PPV for metastatic involvement was 56% on CT [17]. In a retrospective study performed by Ruys et al. histopathological examination of lymph nodes from 147 patients revealed that there is no definite threshold value to predict metastatic involvement [18]. To the best of our knowledge, there is no study in the literature that specifically examined nodal involvement in KTs. In our study, the diagnostic accuracy of nodal metastasis was 69%. However, considering the low number of our cases, the generalizability of this result is limited. Therefore, it appears reasonable to suggest that a confirmatory evaluation with PET should be done in cases of suspected nodal involvement, although a PET-negative result will not rule out nodal metastasis [19].

MRCP imaging has advantages such as being non-invasive compared to invasive ERCP and PTK, panoramic capacity, obviating contrast agent, and visualization of the entire biliary tree. However, MRCP has limitations such as low spatial resolution, inability of showing the complex anatomy of the perihilar bile ducts and superficial spread of the tumor. These limitations are partially offset in 3D MRCP images obtained

with isotropic voxels which can be reformatted in every plane with isotropic resolution [14-16]. We used a 3-dimensional GRE (HYPERCUBE / HYPERSENSE, GE) for MRCP imaging which reduces the partial volume effect for better spatial resolution and uses a navigator allowing the patient to breathe freely.

It has been reported that the diagnostic accuracy in BC classification increased with the addition of DCE MR imaging to MRCP [11]. Although an accurate BC classification may inform the surgeon about the extent of surgery, it cannot adequately assess tumor resectability alone as it does not evaluate other inoperability criteria, including vascular invasion, nodal involvement and distant metastasis.

The surgical approach in resectable KTs varies according to the anatomical location of the tumor and its extension in the bile duct. Generally, endoscopic stenting or surgical hilar resection is performed in Type I and Type II tumors, while percutaneous stenting or major hepatectomy is preferred in Type III tumors. Serious complications such as cholangitis due to catheter manipulation may develop especially after percutaneous stenting [20,21]. Antibiotics given after cholangitis may be ineffective in areas that cannot be drained. Apart from some exceptions, Type IV cases are generally not considered resectable. Therefore, an accurate preoperative BC classification enables to plan surgery or stenting and can predict postoperative complications.

In TNM staging, it is important to make stage distinctions as there are significant prognostic differences between T2 = < and => T3, between N1 and N2, and the presence of distant metastasis according to the 8th AJCC staging. Although the diagnostic accuracy of the T stage in our study is high, it may still be insufficient for surgical planning in some cases, as resectability may also depend on anatomical location (eg in T4 tumors).

Even in resectable conditions, the 5-year survival of KT has been reported as 20-42% with the final outcome mostly determined by nodal metastasis [6,22,23]. Studies with meta-analysis reported low diagnostic accuracy rates in the diagnosis of nodal metastasis with current imaging methods [17,18]. In our study, although the accuracy rate of MRI in detecting nodal metastasis was acceptable, its generalizability is limited. Apart from lymph node size, morphological criteria should also be considered in nodal metastasis in CT and MR. Therefore, in daily practice, TNM staging is performed using postoperative histopathology. Nevertheless, we believe that the correct preoperative TNM staging performed with preoperative dynamic MR will help to evaluate resection possibilities. Also, the addition of MR angiography to DCE/MR may help better evaluate vascular invasion [24]. Finally, a preoperative laparoscopic exploration may be attempted to evaluate peritoneal and distant nodal metastasis in cases interpreted as seemingly resectable Type 3 and T4 KT on MRCP [25].

Our study has several limitations. First, selection bias may be present since only resectable patients were included and unequivocally unresectable patients with high BC type were excluded. Secondly, the retrospective design of the study limited the ability to evaluate parameters that could affect the results. Finally, the study group size is relatively low compared to previous studies.

In conclusion, DCE MRI/MRCP can be used in preoperative staging

of KT to assess biliary tumoral extension and can help in the planning of the appropriate surgical approach. However, it should be remembered that the reliability of MR / MRCP imaging alone in terms of resectability is limited due to the possibility of understaging of Klatskin type, tumor infiltration at the level of hepatoduodenal ligament and the possibility of missing metastatic paraaortic lymph nodes, caval invasion and peritoneal metastases.

Scientific Responsibility Statement

The authors declare that they are responsible for the article's scientific content including study design, data collection, analysis and interpretation, writing, some of the main line, or all of the preparation and scientific review of the contents and approval of the final version of the article.

Animal and human rights statement

All procedures performed in this study were in accordance with the ethical standards of the institutional and/or national research committee and with the 1964 Helsinki declaration and its later amendments or comparable ethical standards. No animal or human studies were carried out by the authors for this article.

Funding: None

Conflict of interest

None of the authors received any type of financial support that could be considered potential conflict of interest regarding the manuscript or its submission.

References

1. Shaib Y, El-Serag HB. The epidemiology of cholangiocarcinoma. *Semin Liver Dis.* 2004;24(2):115-25.
2. Molina V, Sampson J, Ferrer J, Díaz A, Ayuso JR, Sánchez-Cabús S, et al. Surgical treatment of perihilar cholangiocarcinoma: early results of en bloc portal vein resection. *Langenbeck's archives of surgery.* 2017;402(1):95-104.
3. Cho ES, Park MS, Yu JS, Kim MJ, Kim KW. Biliary ductal involvement of hilar cholangiocarcinoma: multidetector computed tomography versus magnetic resonance cholangiography. *J Comput Assist Tomogr.* 2007;31(1):72-8.
4. Zhang H, Zhu J, Ke F, Weng M, Wu X, Li M, et al. Radiological Imaging for Assessing the Resectability of Hilar Cholangiocarcinoma: A Systematic Review and Meta-Analysis. *Biomed Res Int.* 2015;2015:497942.
5. Paul A, Kaiser GM, Molmenti EP, Schroeder T, Vernadakis S, Oezcelik A, et al. Klatskin tumors and the accuracy of the Bismuth-Corlette classification. *Am Surg.* 2011;77(12):1695-9.
6. Amin MB, Edge SB. *AJCC cancer staging manual.* US: Springer; 2017.
7. Hau HM, Meyer F, Jahn N, Rademacher S, Sucher R, Seehofer D. Prognostic Relevance of the Eighth Edition of TNM Classification for Resected Perihilar Cholangiocarcinoma. *J Clin Med.* 2020;9(10):3152.
8. Suarez-Munoz MA, Fernandez-Aguilar JL, Sanchez-Perez B, Perez-Daga JA, Garcia-Albiach B, Pulido-Roa Y, et al. Risk factors and classifications of hilar cholangiocarcinoma. *World J Gastrointest Oncol.* 2013;5(7):132-8.
9. Vogl TJ, Schwarz WO, Heller M, Herzog C, Zangos S, Hintze RE, et al. Staging of Klatskin tumours (hilar cholangiocarcinomas): comparison of MR cholangiography, MR imaging, and endoscopic retrograde cholangiography. *Eur Radiol.* 2006;16(10):2317-25.
10. Zidi SH, Prat F, Le Guen O, Rondeau Y, Pelletier G. Performance characteristics of magnetic resonance cholangiography in the staging of malignant hilar strictures. *Gut.* 2000;46(1):103-6.
11. Park HS, Lee JM, Choi JY, Lee MW, Kim HJ, Han JK, et al. Preoperative evaluation of bile duct cancer: MRI combined with MR cholangiopancreatography versus MDCT with direct cholangiography. *AJR Am J Roentgenol.* 2008;190(2):396-405.
12. Masselli G, Manfredi R, Vecchioli A, Gualdi G. MR imaging and MR cholangiopancreatography in the preoperative evaluation of hilar cholangiocarcinoma: correlation with surgical and pathologic findings. *Eur Radiol.* 2008;18(10):2213-21.
13. Sun HY, Lee JM, Park HS, Yoon JH, Baek JH, Han JK, et al. Gadoteric acid-enhanced MRI with MR cholangiography for the preoperative evaluation of bile duct cancer. *J Magn Reson Imaging.* 2013;38(1):138-47.
14. Lopera JE, Soto JA, Múnera F. Malignant hilar and perihilar biliary obstruction: use of MR cholangiography to define the extent of biliary ductal involvement and plan percutaneous interventions. *Radiology.* 2001;220(1):90-6.
15. Masselli G, Gualdi G. Hilar cholangiocarcinoma: MRI/MRCP in staging and treatment planning. *Abdom Imaging.* 2008;33(4):444-51.
16. Lee SS, Kim MH, Lee SK, Kim TK, Seo DW, Park JS, et al. MR cholangiography versus cholangioscopy for evaluation of longitudinal extension of hilar cholangiocarcinoma. *Gastrointest Endosc.* 2002;56(1):25-32.
17. Noji T, Kondo S, Hirano S, Tanaka E, Suzuki O, Shichinohe T. Computed tomography evaluation of regional lymph node metastases in patients with biliary cancer. *Br J Surg.* 2008;95(1):92-6.
18. Ruys AT, Kate FJ, Busch OR, Engelbrecht MR, Gouma DJ, Van Gulik TM. Metastatic lymph nodes in hilar cholangiocarcinoma: does size matter? *HPB (Oxford).* 2011;13(12):881-6.
19. Huang X, Yang J, Li J, Xiong Y. Comparison of magnetic resonance imaging

and 18-fluorodeoxyglucose positron emission tomography/computed tomography in the diagnostic accuracy of staging in patients with cholangiocarcinoma: A meta-analysis. *Medicine*. 2020;99(35). DOI: 10.1097/MD.00000000000020932.

20. Tang Z, Yang Y, Meng W, Li X. Best option for preoperative biliary drainage in Klatskin tu-mor: A systematic review and meta-analysis. *Medicine (Baltimore)*. 2017;96(43):e8372.

21. Mansour JC, Aloia TA, Crane CH, Heimbach JK, Nagino M, Vauthey JN. Hilar cholangiocar-cinoma: expert consensus statement. *HPB (Oxford)*. 2015;17(8):691-9.

22. Valle JW, Borbath I, Khan SA, Huguet F, Gruenberger T, Arnold D. Biliary cancer: ESMO Clinical Practice Guidelines for diagnosis, treatment and follow-up. *Ann Oncol*. 2016;27(Suppl. 5):v28-v37.

23. Rassam F, Roos E, Van Lienden KP, Van Hooft JE, Klümpen HJ, Van Tienhoven G, et al. Modern work-up and extended resection in perihilar cholangiocarcinoma: the AMC experience. *Langenbecks Arch Surg*. 2018;403(3):289-307.

24. Lee MG, Park KB, Shin YM, Yoon HK, Sung KB, Kim MH, et al. Preoperative evaluation of hilar cholangiocarcinoma with contrast-enhanced three-dimensional fast imaging with steady-state precession magnetic resonance angiography: comparison with intraarterial digital subtraction angi-ography. *World J Surg*. 2003;27(3):278-83.

25. Rotellar F, Pardo F. Laparoscopic staging in hilar cholangiocarcinoma: Is it still justified? *World J Gastrointest Oncol*. 2013;5(7):127-31.

How to cite this article:

Levent Soydan, Mehmet Torun, Kamil Canpolat, Turgay Oner, Umut Kına, Ismail Ege Subasi. The role of magnetic resonance in the staging of Klatskin tumors. *Ann Clin Anal Med* 2021;12(9):963-968